



# AEIG is Simply the Best!

## Leg Infections

At AEIG, you get coverage written by horse people, for horse people. We believe that we offer the most comprehensive and complete coverage for your horse's unexpected medical needs.

But don't take our word for it. Follow along with our monthly comparison series to see how AEIG stacks up to our competitors. Our case studies use actual paid claims and a \$10,000 limit of medical/surgical coverage to compare how different companies cover the same health condition.

We hope to spotlight some of the important details in the fine print of insurance policies that owners should consider. We want you to feel comfortable in the decision you make when choosing an insurance policy for your equine partners.

🐾 Leg infections often present with similar symptoms. Your vet should be contacted to determine the diagnosis and to provide proper treatment.



### AEIG Coverage Highlights

\$2,500 Diagnostic Sublimit

→ No Treatment Sublimit ←

No Copays

**“Stocking up” has a similar swollen appearance of the lower leg, usually both hind, but is not infectious and resolves with exercise.**

### Cellulitis Claim

Case Description: A 15-year-old Warmblood developed cellulitis in his right hind leg. The first episode was treated at home with steroids and antibiotics. Three months later, the infection reoccurred, requiring hospitalization for one week. Diagnostics included a skin biopsy, a fungal culture, urinalysis, and susceptibility testing to determine the appropriate antibiotic. He was treated with antibiotics, anti-inflammatories, omeprazole, IV fluids, cold hosing, and bandage changes.


Total Covered Charges	\$5,771.47
Diagnostic Charges	\$1,084.88
Treatment Charges	\$4,686.59

AEIG		Company A		Company B	
\$2,500 diagnostic sublimit \$400 deductible		20% copay Pos. scope required for ulcers treatment \$500 deductible		\$500 deductible	
Covered Diagnostics	\$684.88	Covered Diagnostics	\$467.90	Covered Diagnostics	\$584.88
Covered Treatments	\$4,686.59	Covered Treatments	\$3,615.59	Covered Treatments	\$4,686.59
<b>Total Paid</b>	<b>\$5,371.47</b>	<b>Total Paid</b>	<b>\$4,083.49</b>	<b>Total Paid</b>	<b>\$5,271.47</b>

## Cellulitis Claim #2

Case Description: A 17-year-old Thoroughbred gelding presented with lameness and swelling in his left front leg. He was referred to a veterinary hospital. Upon arrival he was 4/5 lame, and the left front leg was swollen from the elbow to the hoof and painful to palpation. Bloodwork and ultrasound confirmed a diagnosis of cellulitis. The horse remained hospitalized for two weeks. He was treated with antibiotics, anti-inflammatories, and bandaging. Treatment continued at home until resolved.

Total Covered Charges	\$5,450.70
Diagnostic Charges	\$660.00
Treatment Charges	\$4,790.70

AEIG	Company A	Company B
\$2,500 diagnostic sublimit \$400 deductible	20% copay \$500 deductible	30% diagnostic copay/\$3,000 limit \$400 deductible
Covered Diagnostics \$260.00 Covered Treatments \$4,790.70	Covered Diagnostics \$128.00 Covered Treatments \$3,832.56	Covered Diagnostics \$182.00 Covered Treatments \$4,790.70
<b>Total Paid</b>  <b>\$5,050.70</b>	<b>Total Paid</b> <b>\$3,960.56</b>	<b>Total Paid</b> <b>\$4,972.70</b>

### Lymphangitis

- Inflammation of the lymphatic system.
- A form of chronic cellulitis due to impaired lymphatic drainage.
- Pooling causes lymphatic fluid to become stagnant and bacteria to proliferate.

VS

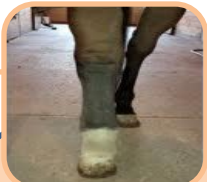### Cellulitis

- 🐾 A bacterial infection of the soft connective tissues under the skin.
- 🐾 Most commonly occurs in the hind legs but can occur in any leg.
- 🐾 Horses that have had cellulitis are more prone to developing it again.

VS

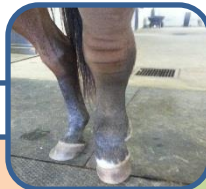### Vasculitis

- > Inflammation of blood vessel walls, usually secondary to another condition.
- > Can be an immune reaction against bacteria, a virus, organism, or a drug/medication.
- > Can be caused by a localized infection or toxins.



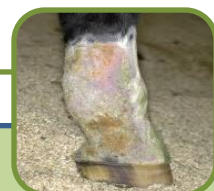#### Symptoms

- Sudden, extreme swelling in one or more legs. Usually starting from the hoof up.
- Hot, painful to touch, cracks in skin, seeping serum, leg abscesses.
- Lameness
- Fever
- Depression



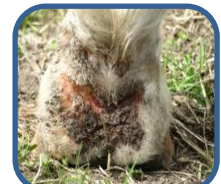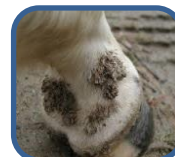#### Treatments

- > Antibiotics
- > Hand walking
- > Cold Therapy
- > DMSO
- > NSAIDs
- > Corticosteroids



### Scratches

- 🐾 Enlargement of the skin cells, with oozing and sores on the back of the pastern and fetlock.
- 🐾 Associated with a wet, muddy environment, or poor stable hygiene.
- 🐾 Heavy horse breeds and white skinned legs are more susceptible.
- 🐾 Also known as Pastern Dermatitis, Dew Poisoning, Mud Fever, and Greasy Heel.
- 🐾 Can affect any leg.

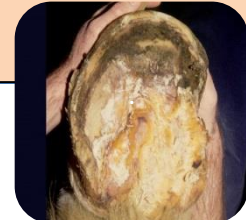
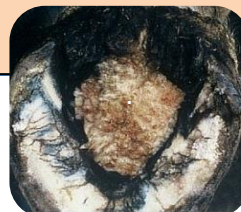
## Lymphangitis Claim

Case Description: A 13-year-old pony mare was diagnosed with lymphangitis. She was hospitalized for treatment for 9 days. She was treated with multiple antibiotics, DMSO, NSAIDs, and given prophylactic Gastrogard.		Total Covered Charges	\$2,984.48
		Diagnostic Charges	\$275.00
		Treatment Charges	\$2,709.48
AEIG	Company A	Company B	
\$2,500 diagnostic sublimit \$400 deductible	20% copay Pos. scope required for ulcers treatment \$500 deductible	Pos. scope required for ulcers treatment \$500 deductible	
Covered Diagnostics \$0.00 Covered Treatments \$2,584.48	Covered Diagnostics \$0.00 Covered Treatments \$1,889.98	Covered Diagnostics \$0.00 Covered Treatments \$2,462.48	Covered Diagnostics \$0.00 Covered Treatments \$2,462.48
<b>Total Paid</b> <b>\$2,584.48</b>	<b>Total Paid</b> <b>\$1,889.98</b>	<b>Total Paid</b> <b>\$2,462.48</b>	

## Canker

- ✦ An infectious process which produces chronic enlargement and proliferation of the horn-producing tissues of the hoof.
- ✦ Usually originates in the frog but if left untreated can spread to adjacent sole, bars, and hoof wall.
- ✦ The lesion has a characteristic cauliflower-like look – white/grey that is moist and spongy.
- ✦ Unsanitary conditions have not been linked to this rare condition. The causative bacteria is unknown.



## Canker Claim

Case Description: A 13-year-old Friesian stallion required hospitalization to treat severe thrush and canker of his left front foot. The initial hospitalization was for one month and included wound debridement, bandaging, NSAIDs, and antibiotics. When he returned home, the condition deteriorated and he was returned to the hospital for further treatment and to allow the condition to clear up completely.		Total Covered Charges	\$4,483.00
		Diagnostic Charges	\$609.00
		Treatment Charges	\$3,874.00
AEIG	Company A	Company B	
\$2,500 diagnostic sublimit \$400 deductible	30% diagnostic copay \$500 deductible	30% diagnostic copay/\$3,000 limit \$400 deductible	
Covered Diagnostics \$209.00 Covered Treatments \$3,874.00	Covered Diagnostics \$76.30 Covered Treatments \$3,874.00	Covered Diagnostics \$146.30 Covered Treatments \$3,874.00	Covered Diagnostics \$146.30 Covered Treatments \$3,874.00
<b>Total Paid</b> <b>\$4,083.00</b>	<b>Total Paid</b> <b>\$3,950.30</b>	<b>Total Paid</b> <b>\$4,020.30</b>	

Watch your in-box the 2<sup>nd</sup> Tuesday of each month. Our next topic will be reproduction. If there is a topic you would like us to cover, please let us know.

- All trademarks and tradenames used are acknowledged to be the copyright of their respective owners.
- Prices and coverage descriptions in the illustrations and comparisons are based on the respective carrier's filed rating and filings with various state insurance departments as of March 1, 2018.
- Claims comparisons assume all claims are adjusted in the same manner applying equine industry claims handling standards.
- Price, coverage and claims comparison information is for personal use and guidance only and does not constitute any contractual representation, warranty or obligation on our part.
- Liability for errors, omissions or consequential loss is expressly disclaimed.